

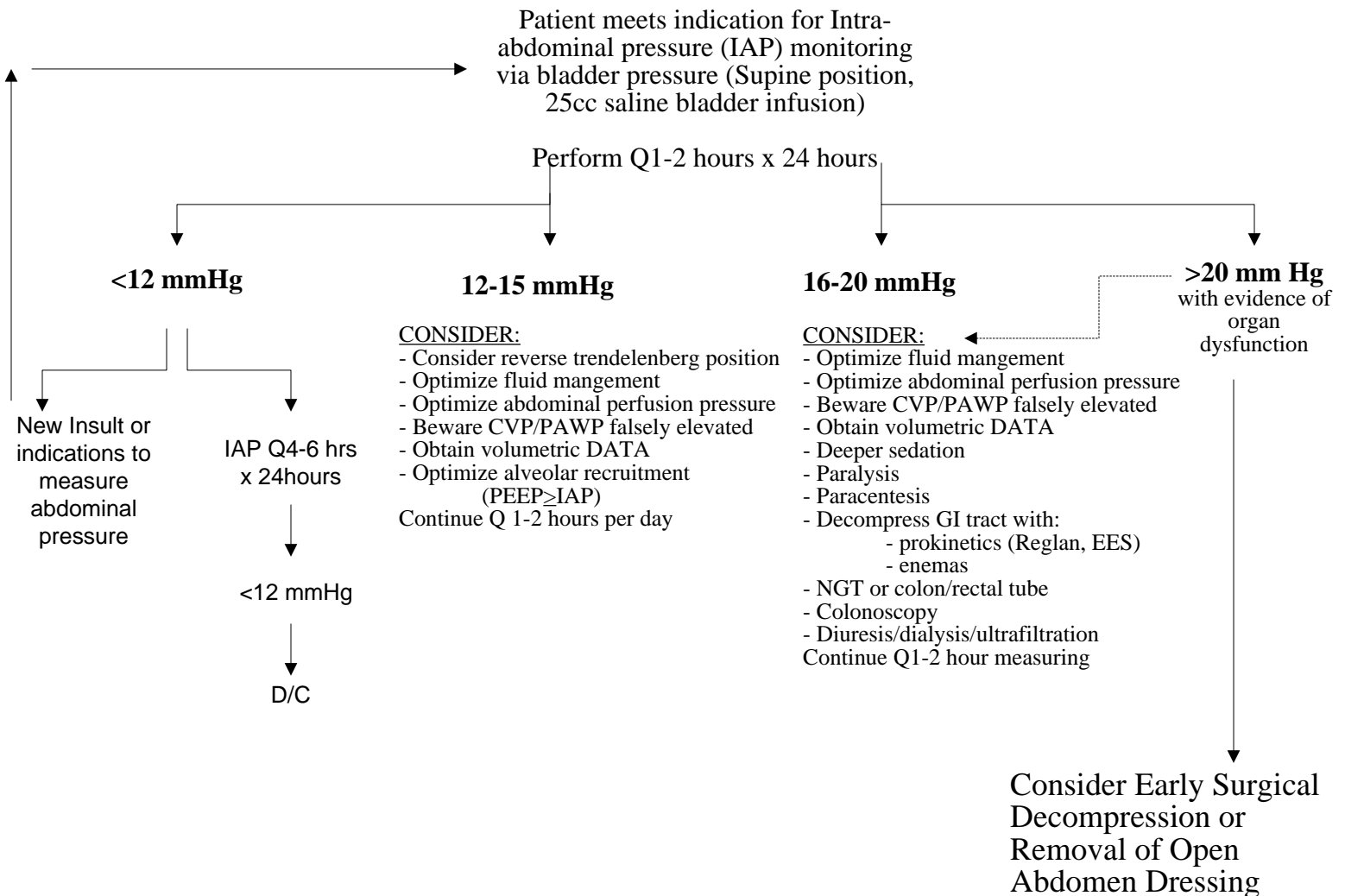
VANDERBILT UNIVERSITY MEDICAL CENTER
DIVISION OF TRAUMA AND SURGICAL CRITICAL CARE

Bryan Collier, DO, FACS

Intra-abdominal HTN and Abdominal Compartment Syndrome – Revised 5/10/2011

Indicators:

- Use of massive transfusion protocol
- Severe SIRS/Sepsis or Shock requiring $\geq 4L$ crystalloid
- Large ventral hernia repair including closure of open abdomen
- Damage control laparotomy/Open abdomen
- Intractable intracranial HTN (ICP >20 despite medical management)



REFERENCES:

Malbrain et al. Intensive Care Med (2006) 32:1722-1732.

Cheatham et al. Intensive Care Med (2007) 33:951-962.

Ivatury et al. Abdominal Compartment Syndrome textbook. 2006